Ulutas Med J 2016;2(1):55-58
DOI: 10.5455/umj.20160210060527

CASE REPORT OPEN ACCESS

A 20 Years Delayed Diagnosis of Foreign Body Aspiration: Wishbone

Ahmet Uluşan[1] **İlknur Aytekin**[2] **Maruf Şanlı**[2] **Levent Elbeyli**[2]

[1]Hitit University Corum Training and Research Hospital, Clinic of Thoracic Surgery, Corum, Turkey
[2]Gaziantep University, Faculty of Medicine, Department of Thoracic Surgery, Gaziantep, Turkey

Abstract

Introduction: Multiple foreign body aspiration (FBA) into the airway is an emergency condition, which is frequently encountered in emergency services, requires immediate intervention, and could lead to troublesome situation in case of delayed diagnosis and treatment. A detailed anamnesis plays an important role in diagnosis. Overlooked or delayed diagnosis could lead to unintended situations that might result in loss of lung tissue.

Case Presentation: We present a 71-year-old female patient who aspirated a wishbone 20 years ago and did not consult a physician due to regression of her complaints. The patient was referred to our clinic with hemoptysis. A foreign body was detected in her airway and accordingly she had to undergo left pneumonectomy, which suggested that delayed diagnosis of FBA leads to serious problems including loss of lung tissue, as was in the present case.

Conclusion: In such cases, physical examination should be performed cautiously and a precise radiological scanning should be carried out. We recommend rigid or flexible bronchoscopy in the event of suspicious FBA into the airway.

Keywords: Foreign body, respiratory aspiration, delayed diagnosis

Introduction

Multiple Foreign body aspiration (FBA) into the airway is a sudden and life-threatening condition that causes many complications and usually requires emergency intervention. FBA is generally seen in children; although rare, it may also be encountered in adults (1). Of the pediatric FBA cases, 80% are below the age of 15 years (2). FBA is more frequent in children as their swallowing functions and neurological and dental structures have not developed completely. Although FBA is rarely encountered in adults, many predisposing factors have been reported including neurological and muscular diseases, alcohol consumption, head trauma, and use of audio devices (3). In the USA, approximately 500-2000 deaths due to FBA have been reported each year (4). An aspirated foreign body may lead to acute respiratory distress in case it obstructs a great part of the airway, whereas a smaller aspirated foreign body may cause

Corresponding Author: Ahmet Ulusan; Hitit University Corum Training and Research Hospital, Clinic of Thoracic Surgery, Corum, Turkey
E-mail: draulusan@gmail.com
Received: Dec 22, 2016 **Accepted**: Feb 10, 2016
Published: March 30, 2016

This is an Open Access article distributed under the terms of the Creative Commons Attribution Non-Commercial License which permits unrestricted non-commercial use, distribution, and reproduction in any area, provided original work is properly cited.

The Ulutas Medical Journal © 2014

symptoms such as coughing, hemoptysis or shortness of breath by generally moving into the distal airways. Although FBA is usually considered as a condition requiring emergency intervention, complications such as pneumonia, atelectasis, lung abscess, empyema, bronchiectasis, and stricture are mostly encountered in the event of late diagnosis and treatment (5, 6). Even a thoracotomy may be required in such cases (7). Herein, we aimed to present a case of left pneumonectomy in a female patient who aspirated a wishbone 20 years ago. With this case report, we aimed to contribute to the literature by demonstrating significant pulmonary problems caused by FBA in case of its late diagnosis.

Case Presentation

A 71-year-old Syrian female patient, who had had a complaint of coughing up blood for approximately two years, was referred to our clinic for the etiology of hemoptysis to be investigated. Detailed medical history of the patient, which was obtained with the help of a translator, revealed that she had had occasional hemoptysis for approximately 2 years and progressively increasing shortness of breath for the last 5 years. However, the patient stated that she had never consulted a physician because of social conditions in Syria, where she had been living. When the medical history of the patient was further investigated, the patient mentioned that she had experienced sudden coughing and shortness of breath while eating chicken 20 years ago; however, she had never consulted a physician because her complaints had relieved. On her physical examination, decreased respiratory sounds and predominating crackles on auscultation with increased dullness on percussion were determined on the left side. Posteroanterior chest X-ray showed reduced ventilation on the left side, deviation of the mediastinum to the left and there were patchy bronchiectatic formations in the parenchyma. Computed tomography (CT) of the thorax was performed on the patient. In the thoracic CT, opacity with bone density was observed in the left main bronchus (Figure-1).

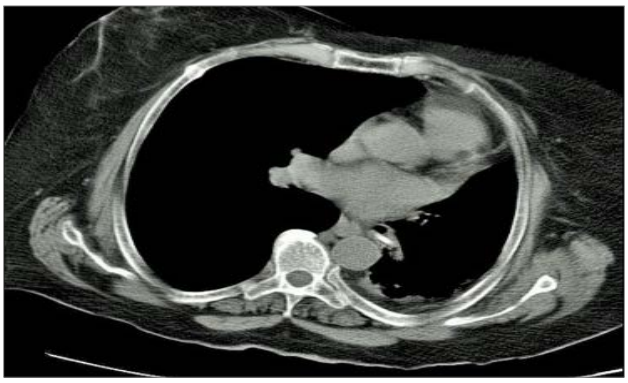

Figure-1. Image of foreign body (bone fragment) on thoracic computed tomography.

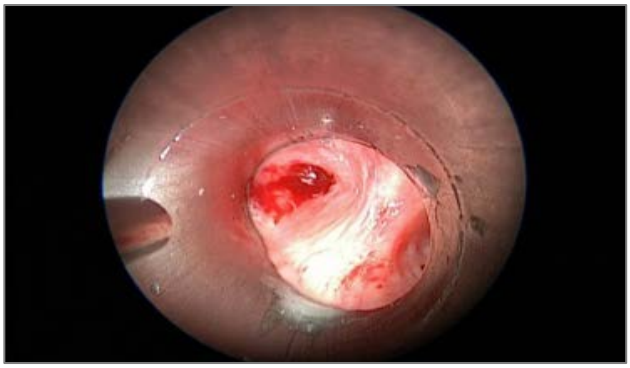

Figure-2. Image of the granulation tissue in the left main bronchus on rigid bronchoscopy.

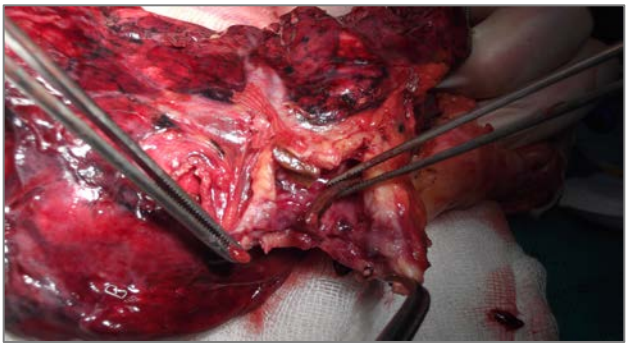

Figure-3. Image of the left pneumonectomy material showing the foreign body in the upper and lower lobes of the left lung

In addition, reduced ventilation in the left lung and bronchiectatic formations were observed. The patient was prepared for rigid bronchoscopy and if required for fiber optic bronchoscopy (FOB). Rigid bronchoscopy was performed under general anesthesia. It was observed that the left main bronchus was obstructed by granulation tissue (Figure-2).



Figure-4. Image of the removed foreign body (a wishbone).

The granulation tissue was tried to be excised using forceps. The procedure was discontinued due to excessive bleeding and failure in reaching to the foreign body. Thereafter, left thoracotomy was planned for the patient. Bronchotomy was performed by turning the tip of bronchoscope to the left main bronchus; however, foreign body could not be found. Left pneumonectomy was decided to be performed due to poor pulmonary ventilation during the operation, unhealthy parenchymal structure, and failure in reaching to the foreign body. The procedure was finalized without any complication. Lobar bronchi of the resected left lung were opened after the surgery. A wishbone extending to the upper and middle lobes was encountered (Figure-3 and Figure-4). After being followed in the intensive care unit for 1 day, the patient was transferred to the ward. No complication was observed during follow-up period and the patient was discharged from the hospital with recommendations.

Discussion

Bronchoscopic methods are the gold standard in the diagnosis and treatment of tracheobronchial foreign body (8,9). It remains a debatable issue whether the bronchoscopic method would be FOB or rigid bronchoscopy (10). The primary approach recommended on this issue is to perform rigid bronchoscopy in conditions, such as emphysema or decreased ventilation in a hemothorax, resulting from obstruction due to size of the foreign body; otherwise, it is recommended to perform FOB firstly for determining the localization of foreign body and then rigid bronchoscopy for removal of it (11).

In our clinic, we first perform rigid bronchoscopy for patients who present with FBA and FOB is performed when a foreign body is detected in distal airways. However, current studies have revealed that the use of FOB technique in the treatment of FBA is gradually increasing with high success rates (3, 8, 12, 13). However, success rates reported in the published studies could not reach to those obtained by rigid bronchoscopy (3, 8, 12). Accordingly, rigid bronchoscopy has been performed in FBA cases, in which FOB has failed (13). In a study conducted in Turkey, 28 adult FBA patients were evaluated; FOB was performed for diagnostic purposes in 5 patients and a foreign body was removed by FOB only in 3 of the patients (13).

Thoracotomy can be required at a rate of 2% in FBA cases in which foreign body could not be removed by endoscopic procedures (14). In thoracotomy, a foreign body can be removed by bronchotomy or lung resection can be performed according to the symptoms, in case of permanent injury in the pulmonary parenchyma, and due to the fact that injury to

one side of the lung may affect contralateral side. In the present case, we tried to remove the foreign body by bronchoscopic intervention for three times; however, we failed despite excision of granulation tissue. During open surgical intervention, bronchotomy should be primarily performed to remove the foreign body. However, lung resection can be performed in patients with an impaired parenchyma and, as the last option, in case of failure to remove the foreign body. Likewise, we also had to perform lung resection in the present case due to the facts that we failed to remove the foreign body and the lung was damaged.

In conclusion, FBA is a clinical emergency condition. Endoscopic intervention should be performed following detailed physical examination and radiological analyses in cases with suspicious FBA despite regression of their complaints. FBA may cause loss of lung tissue by leading to permanent lung injury in patients with delayed diagnosis. A case presenting with FBA should immediately be prepared for endoscopic procedures after providing appropriate conditions and physicians should be ready for surgical intervention in case of failure to remove foreign bodies or due to possible development of complications.

Reference

1. Childs Baharloo F, Veyckemans F, Francis C, Biettlot MP, Rodenstein DO. Tracheobronchial foreign bodies: presentation and management in children and adults. Chest 1999;115:1357-62.
2. Rafanan AL, Mehta AC. Adult airway foreign body removal. What's new?. Clin Chest Med 2001;22:319-30.
3. Mise K, Jurcev Savicevic A, Pavlov N, Jankovic S. Removal of tracheobronchial foreign bodies in adults using flexible bronchoscopy: experience 1995-2006. Surg Endosc 2009;23:1360-4.
4. Limper AH, Prakash UB. Tracheobronchial foreign bodies in adults. Ann Intern Med 1990;112:604-9.
5. Sahin E, Karadayı S, Kaptanoglu M. Tracheobronchial Foreign Bodies. Türkiye Klinikleri J Thor Surg-Special Topics 2009;2:32-7.
6. McGuirt WF, Holmes KD, Feehs R, Browne JD. Tracheobronchial foreign bodies. Laryngoscope 1988;98:615-8.
7. In Turkish: Yıldızeli B, Yüksel M. Yabancı Cisim Aspirasyonları. In: Yüksel M, Kaptanoğlu M, eds. Pediatrik Göğüs Cerrahisi. İstanbul: Turgut Yayıncılık; 2004. p. 151-65.
8. Rodrigues AJ, Oliveira EQ, Scordamaglio PR, Gregório MG, Jacomelli M, Figueiredo VR. Flexible bronchoscopy as the first-choice method of removing foreign bodies from the airways of adults. J Bras Pneumol 2012;38:315-20.
9. Shlizerman L, Mazzawi S, Rakover Y, Ashkenazi D. Foreign body aspiration in children: the effects of delayed diagnosis. Am J Otolaryngol 2010;31:320-4.
10. Erol MM, Ciftci H, Döngel I. Current Approach for Trachea Bronchial Foreign Body Aspirations. Selçuk Tıp Derg 2012;28:201-4.
11. Martinot A, Closset M, Marquette CH, Hue V, Deschildre A, Ramon P, et al. Indications for flexible versus rigid bronchoscopy in children with suspected foreign-body aspiration. Am J Respir Crit Care Med 1997;155:1676-9.
12. Dong YC, Zhou GW, Bai C, Huang HD, Sun QY, Huang Y, et al. Removal of tracheobronchial foreign bodies in adults using flexible bronchoscopy: experience with 200 cases in China. Intern Med 2012;51:2515-9.
13. Ozdemir C, Sökücü SN, Karasulu L, Büyükkale S, Dalar L. Foreign Body Aspiration in Adult: Analysis of 28 Cases. Eurasian J Pulmonol 2015;17:29-34.
14. In Turkish: Karadayı S, Kaptanoglu M. Yabancı Cisim Aspirasyonları. In: Okten I, Kavukçu HS, eds. Göğüs Cerrahisi, Türk Göğüs Cerrahisi Derneği. 2nd ed. İstanbul: İstanbul Medikal Sağlık ve Yayıncılık; 2013. p. 859-64.

How to cite?

Ulusan A, Aytekin I, Sanlı M, Elbeyli L. A 20 Years Delayed Diagnosis of Foreign Body Aspiration: Wishbone. Ulutas Med J. 2016;2(1):55-58.

DOI: dx.doi.org/10.5455/umj.20160210060527

Why the Ulutas Medical Journal ?

- Convenient online Pdf submission
- Fast response through peer review
- No space constraints or color figure charges
- Immediate publication after acceptance
- Inclusion in Scopemed and Google Scholar

To submit your manuscript, please click on
http://ulutasmedicaljournal.com